

ISSN : 0929-1881

An abstract graphic consisting of a grid of thin, light blue lines that wave and curve across the page, creating a sense of motion and depth. The lines are more densely packed in some areas and more sparse in others, giving it a three-dimensional appearance.

**ADVANCED
PERFORMANCE MATERIALS**

IMPORTANCE OF CORONAVIRUS INFECTION (COVID-19) IN THE DEVELOPMENT OF SYSTEMIC VASCULITIS

Djurayeva E.R., Normuradov A.D.

Tashkent medical academy Uzbekistan

Abstract. Environmental change, climate warming, increasing population density, high migration activity of the population and other factors provoke the emergence and spread of new infections around the world.

The emergence in December 2019 of diseases caused by the new coronavirus (“coronavirus disease 2019”) has already gone down in history as an emergency of international concern. It is known that the most common clinical manifestation of a new infection is pneumonia, as well as respiratory distress syndrome in a significant proportion of patients. Our article presents a brief analytical review of the temporary guidelines of the Ministry of Health of the Russian Federation "Prevention, diagnosis and treatment of a new coronavirus infection (COVID-19)", version 3 (03.03.20) and other literature sources. The team of authors hopes that these data will be useful to doctors in providing medical care to patients with a new coronavirus infection, as well as teachers in the preparation of students and residents.

Keywords: COVID-19, coronavirus, clinic, vasculitis, diagnostics, prevention

As already known, the SARS-CoV-2 virus infects blood vessels and causes thrombotic catastrophes in the body. SARS-CoV-2 infection is involved in the induction of endotheliitis as a direct consequence of viral infection and host inflammatory response. Illustrative case history of a patient with IgA vasculitis associated with COVID-19 published in *Arthritis & Rheumatology* (<https://doi.org/10.1002/art.41428>)

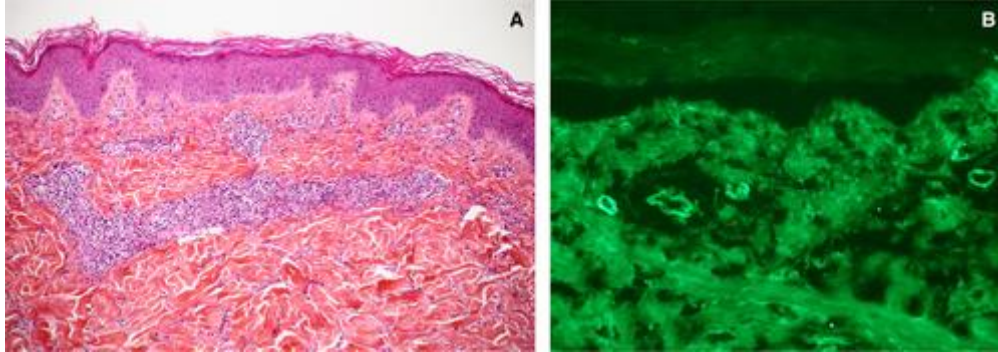
Systemic vasculitis is a heterogeneous group of diseases, the main morphological feature of which is inflammation of the vascular wall, and clinical manifestations depend on the type, caliber, localization of the affected vessels and the activity of systemic inflammation. Systemic vasculitis is a relatively rare disease: the incidence is about 4.2 per 100,000 population per year, but recently there has been a tendency to increase their prevalence in the world.

Immunocomplex small vessel vasculitis includes diseases associated with antibodies to the glomerular basement membrane (anti-GMB); cryoglobulinemic vasculitis; IgA-vasculitis (Schonlein-Genoch); hypocomplementemic urticarial vasculitis (anti-C1q-associated vasculitis).

IgA vasculitis is a systemic small vessel vasculitis that can be caused by various microorganisms.

A 24-year-old man with Crohn's disease was admitted to Saint-Louis, AP-HP and Université de Paris, France with a 9-day skin rash, severe asymmetric arthralgia, periarticular edema, and abdominal pain. He had no respiratory symptoms or fever. In 2016 he was diagnosed with Crohn's disease and in 2017 he underwent an ileocecal resection. After the operation, he received adalimumab, and his disease was in

remission. Despite moderately severe diffuse abdominal pain, he had no intestinal bleeding or diarrhea. On physical examination: palpable purpura on the legs and arms, swelling of the left arm, tenderness on palpation of several joints without signs of arthritis. His pulse and blood pressure were normal.



A nasopharyngeal swab for COVID-19 was performed on admission and was positive (PCR) (Xpert Xpress SARS-CoV-2). Blood cell counts, urinalysis results, liver test results, creatinine and lipase levels were normal. Elevated levels of C-reactive protein (44 mg/l), d-dimer (5470 ng/ml), fibrinogen (4.6 g/l) and complement C4 (0.48 g/l) were found. No other viral agents were found.

Serum IgA levels were markedly increased (5.3 g/L), while IgG and IgM levels were normal. Serological testing for COVID-19 (Euroimmune) detected IgA but not IgG, and when tested again 10 days later, the patient was negative for both IgA and IgG. Although nasopharyngeal swab results were positive for COVID-19 on admission, they became negative as early as 2 days after admission, and stool PCR testing for SARS-CoV-2 was negative initially.

Computed tomography (CT) showed widespread ileitis with marked bowel wall thickening and mucosal and submucosal edema consistent with vasculitis. CT scan of the chest revealed no pathology.

Skin biopsy confirmed the diagnosis of IgA vasculitis with perivascular infiltration of vessel walls by neutrophils and lymphocytes, leukocytoclasia, and deposits of C3 and IgA in skin capillaries identified by immunofluorescent staining.

Skin biopsy shows small vessel vasculitis of the superficial dermis with lymphocytes, neutrophils, and leukocytoclasia (A), with deposits of IgA (B) and C3, but not IgG, on the surface of skin capillaries, revealed by direct immunofluorescence staining of the skin. Original magnification $\times 10$ A , $20 \times$ B .

LMW heparin and intravenous steroids (methylprednisolone) were started 2 days after hospitalization for severe abdominal pain. The patient was discharged on the 7th day receiving oral steroids and enoxaparin.

This case of IgA vasculitis in a patient with Crohn's disease receiving therapy is notable for several reasons. Firstly, it was associated with COVID-19, which was confirmed by PCR and serological studies. The patient was hospitalized during the peak of the COVID-19 pandemic and had contact with several people who were potentially positive for COVID-19 but were not tested. Laboratory diagnostics showed high levels of d-dimer and inflammatory markers, indicating a hypercoagulable state, which is one of the markers of COVID-19. The second notable

finding was high serum IgA levels with a weak and transient positive for IgA only on serological testing for COVID-19. As previously reported, SARS-CoV-2 IgA is the first immunoglobulin detected after infection with COVID-19 (PMID: 32343948). There is some evidence that other IgA-associated diseases are associated with COVID-19. Indeed, one report has suggested a possible link between COVID-19 and Kawasaki disease (PMID: 32410759), a systemic vasculitis associated with an antigen-dependent IgA response (PMID: 16339580). Interestingly, increased intestinal permeability has been reported in this disease, suggesting that gut barrier dysfunction plays a role in the development of IgA vasculitis (PMID: 31471109). In addition, frostbite lesions have been reported to be associated with COVID-19 infection, with anti-COVID-19 serological tests detecting IgA but not IgG in these patients (<https://doi.org/10.1111/bjd.20707>). Notably, in this patient, IgA vasculitis was associated with elevated serum IgA and only with IgA detected in the COVID-19 serology test.

Based on the concept of angiotensin-converting enzyme 2 (ACE2) as the main receptor for coronavirus-2 associated with the development of severe acute respiratory syndrome (SARS-CoV-2), hematogenous spread of the virus with subsequent death of ACE2-expressing cells in the walls of microvessels is assumed. Damage to the walls of blood vessels, primarily arterioles, leads to the development of microthrombosis and results in the release of the liquid phase of the blood beyond the vascular bed, which is pathogenetically similar to the development of angioedema. The disorders arising as a result of this are of a multi-organ nature, and in the case of lung tissue, they occur according to the type of "pulmonary edema", the instrumental picture of which, during computed tomography, precedes the development of respiratory failure. The proposed scheme of the pathogenesis of COVID-19 makes it possible to explain the causes and sequence of occurrence of many symptoms of this disease. Possible changes in the protocols for diagnosing and treating COVID-19 are discussed.

Key words: COVID-19, angiotensin-converting enzyme 2, pathogenesis.

Our search for the causes of skin pathology in COVID-19 (from the English CORonaVirus Disease 2019), analysis of cases of coronavirus infection that have become public, as well as a study of the opinion of practicing physicians, leading patients with COVID-19, led us to assume that its perception as a "new severe acute respiratory viral infection" may be incorrect, and the assessment of the resulting lung damage as "pneumonia" may be erroneous.

Pathogenesis

Our hypothesized pathogenesis of COVID-19 is as follows:

- the main mechanism of SARS-CoV-2 attachment

(severe acute respiratory syndrome-related coronavirus 2) to target cells is the interaction of a glycoprotein on the processes of the viral supercapsid with a membrane protein, angiotensin-converting enzyme 2 (ACE2);

- since the function of ACE2 is the conversion of the vasoconstrictor angiotensin II to vasodilator angiotensin (1–7), its typical localization is in the

endothelial and smooth muscle cells of small vessels (mainly arterioles), where ACE2 is involved in the regulation of blood pressure;

- a consequence of virus replication in cells expressing ACE2 is the exposure of viral protein fragments together with the class I major histocompatibility complex, inducing a T-cell immune response;

- manifestation of the immune response is the production of pro-inflammatory interleukins and activation of cytotoxic T-lymphocytes, and its result is the death of ACE2-expressing cells in arterioles with the induction of intravascular coagulation and impaired microcirculation, culminating in the release of the liquid part of the blood beyond the vascular bed;

- the most pronounced damage occurs in organs in which the microvascular bed already has pre-existing disorders; the intensity of the exit of the liquid part of the blood increases with a high level of blood pressure.

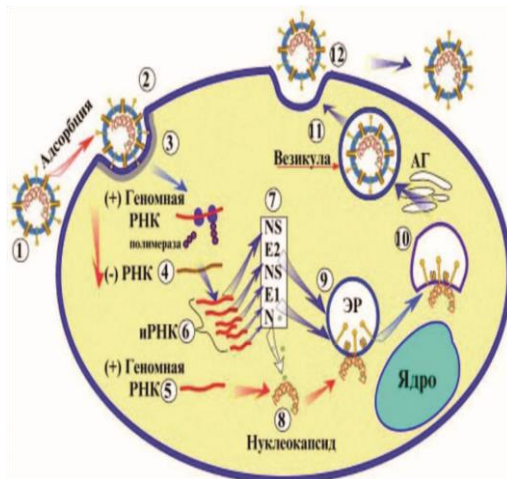
116 According to these concepts, COVID-19 is a generalized viral vasculitis with pathogenetically significant arteriole damage, and the resulting lesion of the lung tissue is a variant of angiogenic pulmonary edema.

The proposed scheme of pathogenesis allows a good explanation of most of the symptoms of COVID-19, including the nature of changes in the lungs during computed tomography (CT) - a symptom of "ground glass"; the initial absence of clinical symptoms of pneumonia with a pronounced CT picture of lung tissue damage; manifestation of a mesh vascular pattern on the skin, multiple organ lesions.

Within the framework of the proposed concept, the violation of the perception of taste and smell, as well as the decrease in hemoglobin level that develops in the dynamics of the disease, which can probably be determined by the "alternative" mechanism of SARS-CoV-2 binding to target cells through CD-147 (in particular, with nerve cells expressing this receptor and cells participating in erythropoiesis). At the same time, the use of this possibility for penetration into erythrocytes is unlikely, since the lack of a sufficient biosynthetic apparatus in them makes this pathway a "dead end" for the virus.

In general, the development of COVID-19 can be divided into three stages:

1) the stage of incubation, during which the virus is in the nasopharynx, clinical manifestations are minimal or absent;



2) the stage of generalization, during which the virus spreads through the vascular bed, infects ACE2-expressing cells and induces an immune response; clinical manifestations are the development of fever;

3) the stage of multiple organ failure, the clinical manifestations of which are a violation of the functioning of organs with the most pronounced damage to the microvascular bed.

Possible changes in laboratory diagnosis and therapy

If the proposed scheme of the pathogenesis of COVID-19 is correct, its adoption should lead to a change in a number of approaches to laboratory diagnosis and therapy of this disease.

When conducting laboratory diagnostics using the polymerase chain reaction (PCR), the main changes should affect the preanalytical stage associated with the targeted selection of virus-containing samples of biological material. Taking smears from the nasopharynx can be recommended only at the early stages of the infectious process, while at the stage of generalization for PCR diagnostics, blood samples from the microvascular bed should be submitted, and at later stages, biopsy specimens of target organs.

Another important issue requiring further study may be the state of reproductive functions in men after suffering COVID-19. The reason for this is the highest level of ACE2 expression in the germinal cells of the testicles, which suggests the possibility of their intense infection. Publications on this issue are so far isolated, and the results presented in them are often contradictory, which is obviously due to the short observation period.

In turn, a possible correction in the treatment regimens may be associated with a change in the means and methods of combating respiratory failure, including the prevention of thrombosis in the arterioles of the pulmonary circulation and the restoration of microcirculation, limiting fluid intake and refusing intravenous infusions when CT manifestations of pulmonary edema appear, possible use of diuretics, use of mechanical ventilation protocols developed for the treatment of pulmonary edema.

Literature / References:

1. World Health Organization. Clinical guidelines for the management of patients with severe acute respiratory infection for suspected novel coronavirus (2019-nCoV) infection. Temporary recommendations. Publication date: January 25, 2020 [Electronic resource]. URL: http://www.euro.who.int/__data/assets/pdf_file/0020/426206/RUSClinical-Management-ofNovel_CoV_Final_without-watermark.pdf?ua=1. (accessed 03/23/2020)

2. Coronavirus (Covid-19). [Electronic resource]. URL: <https://coronavirusmonitor.ru>. (accessed 03/23/2020) Coronavirus (Covid-19). [Electronic resource]. URL: <https://coronavirusmonitor.ru>. (date of the application: 23.03.2020) [In Russian]

3. Alserehi H., Wali G., Alshukairi A., Alraddadi B. Impact of Middle East respiratory syndrome coronavirus (MERS-CoV) on pregnancy and perinatal outcome. *BMC Infect Dis.* 2016; 16:105-108.

4. Bassetti M. The Novel Chinese Coronavirus (2019-nCoV) Infections: challenges for fighting the storm. <https://doi.org/10.1111/eci.13209> URL: <https://onlinelibrary.wiley.com/doi/abs/10.1111/eci.13209>

5. Gu J., Han B., Jian Wang J. COVID-19: Gastrointestinal manifestations and potential fecal-oral transmission. *gastroenterology.* 2020. <https://doi.org/10.1053/j.gastro.2020.02.054>

6. Cao B., Wang Y., Wen D. et al. A Trial of Lopinavir–Ritonavir in Adults Hospitalized with Severe Covid-19. *New England Journal of Medicine.* 2020; DOI: 10.1056/NEJMoa2001282.

7. Zhang L., Lin D., Sun X. et al. Crystal structure of SARS-CoV-2 main protease provides a basis for design of improved α -ketoamide inhibitors. *Science.* 2020. doi. 10.1126/science.abb3405.

8. Federal Service for Supervision of Consumer Rights Protection and Human Welfare. About the new coronavirus infection. [Electronic resource]. URL: https://rospotrebnadzor.ru/region/korono_virus/punkt.php. (Accessed 03/23/2020) Federal Service for Supervision of Consumer Rights Protection and Human Well-Being. About a new coronavirus infection. [Electronic resource]. URL: https://rospotrebnadzor.ru/region/korono_virus/punkt.php. (date of the application: 23.03.2020) [In Russian]